

STUDY PROTOCOL

Open Access



# Total wrist arthrodesis with and without arthrodesis of the carpoMetacarpal joint (WAWWAM): study protocol

David H. Owen<sup>1,2\*</sup> , Diana M. Perriman<sup>1,2</sup>, Igor Policinski<sup>1,2</sup>, Maurizio Damiani<sup>1,2</sup>, Paul N. Smith<sup>1,2</sup> and Chris J. Roberts<sup>1,2</sup>

## Abstract

**Background:** It is controversial whether or not the carpometacarpal joint (CMCJ) should be included in total wrist arthrodesis (TWA). Complications commonly occur at this site and studies examining its inclusion and exclusion are conflicting. A randomised clinical trial comparing wrist arthrodesis with CMCJ arthrodesis and spanning plate to wrist arthrodesis with CMCJ preservation and non-CMCJ spanning plate has not been performed.

**Method:** A single centre randomised clinical trial including 120 adults with end-stage isolated wrist arthritis will be performed to compare TWA with and without the CMCJ included in the arthrodesis. The primary outcome is complications in the first post-operative year. Secondary outcomes are Disabilities of the Arm, Shoulder and Hand (DASH) score, Patient Rated Wrist Evaluation (PRWE) and grip strength measured at 1, 2 and 5 years. Late complications, return to work and satisfaction will also be recorded.

**Discussion:** It is unknown whether the CMCJ should be included in TWA. This trial will contribute to an improved understanding of optimal management of the CMCJ in total wrist arthrodesis.

**Trial registration:** This trial was prospectively registered with the Australia New Zealand Clinical Trials Registry with identifying number ACTRN12621000169842 on the 16th February 2021.

WHO: U1111-12626523.

ANZCTR:

[ACTRN12621000169842](https://www.anzctr.org.au/Trial/Registration/Trial.jsp?ACTRN12621000169842)

\* Correspondence: [david.howen@gmail.com](mailto:david.howen@gmail.com)

A single centre, triple blinded, randomised, parallel group, superiority study to compare the effect of total wrist arthrodesis with spanning plate and carpometacarpal joint arthrodesis to total wrist arthrodesis with non-spanning plate without carpometacarpal joint arthrodesis.

<sup>1</sup>Trauma and Orthopaedic Research Unit, Canberra Hospital, Building 6 Level 1, PO Box Woden ACT, Canberra 2606, Australia

<sup>2</sup>Australian National University Medical School, Level 2 Peter Baume Building 42, Linneaus Way, Canberra 0200, Australia



© The Author(s). 2021 **Open Access** This article is licensed under a Creative Commons Attribution 4.0 International License, which permits use, sharing, adaptation, distribution and reproduction in any medium or format, as long as you give appropriate credit to the original author(s) and the source, provide a link to the Creative Commons licence, and indicate if changes were made. The images or other third party material in this article are included in the article's Creative Commons licence, unless indicated otherwise in a credit line to the material. If material is not included in the article's Creative Commons licence and your intended use is not permitted by statutory regulation or exceeds the permitted use, you will need to obtain permission directly from the copyright holder. To view a copy of this licence, visit <http://creativecommons.org/licenses/by/4.0/>. The Creative Commons Public Domain Dedication waiver (<http://creativecommons.org/publicdomain/zero/1.0/>) applies to the data made available in this article, unless otherwise stated in a credit line to the data.

**Keywords:** Randomised control trial, Surgery, Wrist, Arthrodesis, Carpometacarpal joint, Plate

## Background

Total wrist arthrodesis (TWA) is indicated for a variety of wrist conditions where motion preserving procedures are contraindicated [1]. The aim of TWA is to eliminate pain and provide stability to improve function [2]. TWA with a dorsal contoured wrist arthrodesis plate has been widely adopted [3–9]. Complications of TWA with a plate include non-union, soft tissue irritation and hardware failure. The carpometacarpal joint is a common site of complications [4, 10, 11].

Inclusion of the carpometacarpal joint in TWA is debated and complications at this site are mentioned throughout the literature [2]. Early descriptions of TWA using a plate mandated inclusion of the carpometacarpal joint. Inclusion of this joint is recommended, as persistent loading of the plate across a mobile joint may result in plate failure, and to prevent this plate removal is recommended. Arthrodesis of the CMCJ at the time of TWA is indicated for localised pain or degeneration of the joint. Some authors recommend routinely including the CMCJ in TWA, while others recommend arthrodesis for heavy manual workers.

Nagy recommended against CMCJ arthrodesis noting a high frequency of non-union and pain in patients that had hardware removed [10]. In a similar study, Berling disagreed, instead preferring to fuse the carpometacarpal joint to reduce the requirement for plate removal with a second operation [11]. Rancy compared a non-carpometacarpal spanning plate to a spanning plate with carpometacarpal joint fusion in a small retrospective series and reported similar results for both treatment groups [12]. Most recently, Hernekamp compared the Medartis APTUS® 2.5 TriLock Wrist Fusion Plate, which is a specially designed non-spanning plate that enables the carpometacarpal joint to be spared to the Depuy-Synthes® CMCJ spanning LCP wrist fusion plate without CMCJ arthrodesis, reporting similar results [4].

The advantages of preserving the CMCJ in TWA is that a small amount of motion is preserved in the hand. Seven degrees of flexion/extension, 4 degrees of radio-ulna deviation and 5 degrees of pronation-supination is present in the native third CMCJ [13], which is most commonly fused in TWA. Motion at the CMCJ improves grip strength and the ability to make a fist. Disadvantages of preservation of the CMCJ in TWA are that hypermobility and pain may develop after TWA without CMCJ arthrodesis, which may be explained by increased loading of the CMCJ though an immobile wrist. It is hypothesised that this may cause accelerated degeneration of this joint and pain after TWA.

The total wrist arthrodesis with and without arthrodesis of the carpometacarpal joint study (WAWWAM study) is a single centre, multi-surgeon triple blinded randomised trial that will examine the outcome of two different treatments of the CMCJ in TWA.

## Objectives

The aim of this study is to compare the outcomes of TWA with a CMCJ spanning plate and CMCJ arthrodesis to TWA with a non-spanning plate without CMCJ arthrodesis.

Specific aims:

- To compare perioperative and short-term (up to 12 months) complications
- To compare clinical outcomes: pain, satisfaction, return to work, function, grip strength
- To compare long-term (1–5 years) complications and CMCJ problems
- To compare patient reported outcomes: Disabilities of Arm, Shoulder, Hand (DASH) and Patient Rate Wrist Evaluation (PRWE)

## Methods/design

### Trial design

This study is a single centre randomised trial. It has a parallel group design and is stratified by surgeon. Trial admission and randomisation will occur preoperatively.

### Ethics

Approval for the conduct of this study has been received from the Australian Capital Territory Health (ACT) Services Directorate Human Ethics Committee: 2020.ETH.00207.

### Participants

Adults aged 18 years and older awaiting TWA will be invited to participate in this trial. Participants will be English speaking, have minimal disability of the upper limb and have non-inflammatory arthritis of the wrist. Additional eligibility criteria are specified in Table 1. The CONSORT statement is followed for the reporting of randomised trials. A participant's journey through the trial is shown in Fig. 1.

### Participating hospitals

The following hospitals in the Australian Capital Territory are participating in this study: Canberra Hospital, National Capital Private, Calvary John James and Calvary Bruce.

**Table 1** Eligibility and exclusion criteria

| Eligibility criteria   |  |
|--|--|
| Inclusion criteria   |  |
| This study will include English speaking adults aged > 18 years who have been scheduled for total wrist arthrodesis. The conditions which are likely to be included are: |  |
| SNAC (Scaphoid non-union advanced collapse)  |  |
| SLAC (Scapholunate ligament advanced collapse)   |  |
| Keinbock's disease/Lunate avascular necrosis   |  |
| Preiser's disease/Scaphoid avascular necrosis  |  |
| Wrist osteoarthritis   |  |
| Post traumatic arthritis   |  |
| Failed partial fusion  |  |
| Failed proximal row carpectomy   |  |
| Failed ligament repairs  |  |
| Exclusion criteria   |  |
| Patients will be excluded from this study if they:   |  |
| Lack ability to provide informed consent for participation (cognitive capacity or English proficiency)   |  |
| Have an inflammatory arthropathy (e.g., Rheumatoid arthritis)  |  |
| Have coexisting debilitating other upper limb disorder e.g., rotator cuff tear arthropathy with inability to raise arm above head.                                       |  |
| Neurological dysfunction affecting the limb of interest (CVA, plexus injury, peripheral nerve injury, spasm or contracture)  |  |
| Tumour of the wrist (giant cell or other)  |  |
| Wrist arthroplasty that will be revised to arthrodesis   |  |
| Planned to undergo or have undergone bilateral wrist arthrodesis   |  |

**Baseline data**

A timeline for assessment is given in Fig. 1. Initial pre-operative assessment will obtain data on comorbidities, function, clinical assessment of pain at the CMCJ and radiographic assessment with x-ray and computer

tomography (CT). Patient reported outcome measures including the DASH and the PRWE will also be administered.

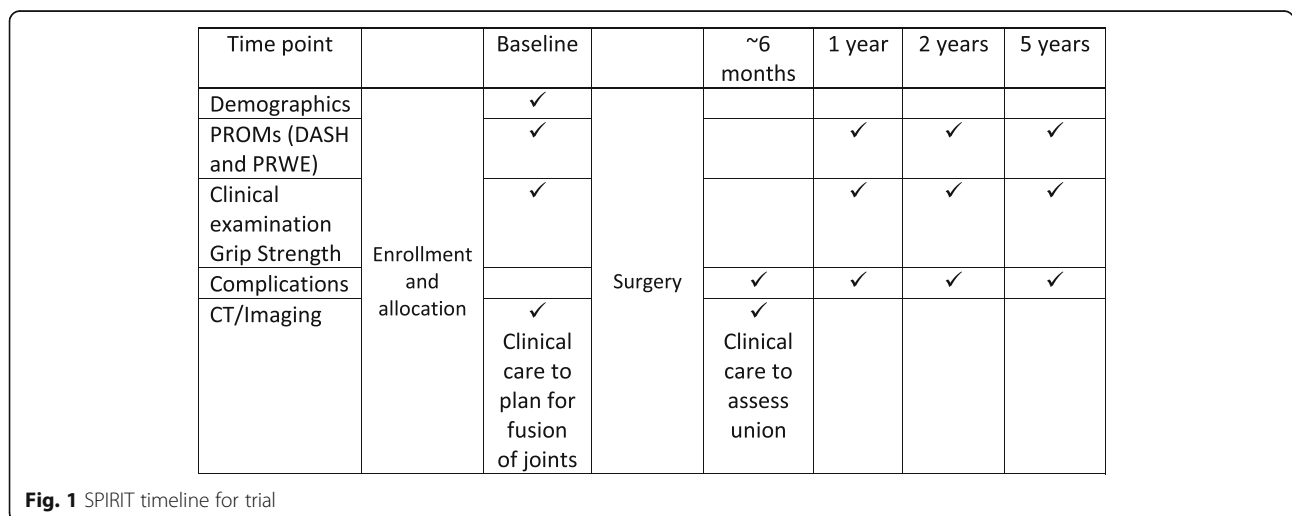
**Randomisation and blinding**

Block randomisation with stratification by surgeon will be used to ensure equal distribution of participants and size of each treatment group in the event that recruitment goals are not achieved. Eligible patients are randomised 1:1 to TWA with CMCJ arthrodesis and spanning plate or TWA without CMCJ arthrodesis with non-CMCJ spanning plate. The randomisation sequence is concealed and administered by an independent non-clinical staff member of the Trauma and Orthopaedic Research Unit at the Canberra Hospital. Letters are then allocated to participating surgeons containing the concealed treatment allocation. In this way the surgeon cannot influence the type of intervention; and the participants, clinical and research staff are blinded.

**Intervention**

A fellowship trained orthopaedic surgeon with subspecialist hand surgery training will undertake the initial patient assessment and perform the surgery. All surgeons are experienced and familiar with both treatments.

Procedures are performed under general anaesthesia with antibiotic prophylaxis and the use of a tourniquet. A dorsal approach with full thickness skin flaps is used and the interval between the 3rd and 4th compartment is developed. In cases of minimal bone loss, local bone graft is used; in cases of advanced bone loss, cortico-cancellous bone graft is obtained from the ipsilateral iliac crest. If the distal radioulnar joint is arthritic, it is resected and used as bone graft. A dorsal capsulotomy is performed to expose the radiocarpal and midcarpal joint



and a posterior interosseous nerve neurectomy is performed.

#### **Treatment a: Total wrist arthrodesis without CMCJ arthrodesis and non-bridging plate**

Care is taken at this point not to damage the CMCJ or joint capsule which is identified by fine bore needle under fluoroscopy. After thorough decortication of the radiocarpal and midcarpal joints the Medartis 2.5 Tri-Lock Wrist Fusion without arthrodesis of the carpometacarpal joint (Medartis, Hochbergerstrasse 60E, 4057 Basel Switzerland) is applied according to manufactures instructions and intra-operative imaging is obtained to ensure correct placement.

#### **Treatment B: Total wrist arthrodesis with CMCJ arthrodesis and bridging plate**

In addition to preparing the radiocarpal and midcarpal joints, the third CMCJ is prepared for arthrodesis. The third metacarpal is marked to ensure correct rotation and a Synthes-DePuy 2.7/3.5 mm stainless steel plate (Synthes-DePuy, Eimattstrasse 34,436 Oberdorf BL Switzerland) is secured and intra-operative imaging is undertaken to confirm correct placement.

For both interventions, bone graft if used, is packed around the decorticated carpal bones. Wounds are closed in layers and interrupted nylon suture is used for skin. The wrist is then placed in a well-padded short arm volar plaster slab. Post-operative rehabilitation is standardised with immediate motion of the shoulder, elbow and fingers. At 2 weeks, participant wounds are checked, and they are supplied with a removable thermoplastic splint.

#### **Outcome assessment**

A timeline for assessment is given in Fig. 1. Surgeons will record peri-operative complications and union on a standardised form. In each outpatient department a blinded physiotherapist will ensure post-operative assessment is completed at 1, 2 and 5 years. Patients will undergo assessment with DASH, PRWE, report pain, satisfaction and record perceived problems or complications.

#### **Primary outcome**

The primary outcome is complication within the 12-month post-operative period. These complications are defined in Table 2. Non-union will be assessed at the radiocarpal, midcarpal and carpometacarpal joint (if arthrodesed) by CT.

#### **Secondary outcomes**

Secondary outcomes will include changes from baseline DASH and PRWE. Secondary outcomes will also

**Table 2** Complications will be defined to include the following

#### **Wound dehiscence**

Infection: superficial (treated with antibiotics alone) and deep (requiring surgical debridement and antibiotics)

Fracture: in the perioperative period and in the follow up period

Non-union: recorded radiocarpal, midcarpal and carpometacarpal joint and defined as absence of bridging bony trabeculae with no interval change over 3 months

Hardware breakage: plate or screw, managed operative or non-operatively

Tendon rupture

Tendon irritation: requiring treatment

Complex regional pain syndrome: defined according to Budapest criteria

Nerve injury: operatively or not operatively managed

Other: medical and surgical

include patient satisfaction, grip strength and late complications.

The DASH questionnaire is used to assess global disability of the upper limb. The questionnaire is a self-reported 30 item questionnaire that patients rate difficulty and interference with daily life on a 5-point Likert scale. The DASH is scored using the formula =  $\left(\frac{\text{sum of } n \text{ responses}}{n}\right) - 1$  where n represents the number of completed items. The score on both test ranges from 0 (no disability) to 100 (most severe disability).

The PRWE is a wrist specific questionnaire that has 15-items designed to measure wrist pain and disability in activities of daily living. The pain subscale contains 5 items each of which is further rated from 1 to 10. The function subscale contains a total of 10 items which are further divided into 2 sections: specific activities (6 items) and usual activities (4 items). Both subscales are scored out of 50, and the total score is the sum of the two scores, where 100 is the poorest possible outcome.

Grip strength will be recorded from three attempts alternating between left and right hands have using Jamar digital dynamometer in position 2.

#### **Radiological evaluation**

Routine x-ray and pre-operative CT will be used to assess the integrity of the CMCJ. Intraoperatively fluoroscopy will be used by the surgeon to assess hardware placement, screw length and position, and alignment and rotation of the hand.

Union of the radiocarpal, midcarpal and carpometacarpal joint will be assessed by an independent specialist radiologist at 4–6 months following TWA and be defined as the presence of bridging bony trabeculae.

Non-union will be defined as the absence of bridging trabeculae, with no documented interval change over a 3-month period.

### Data collection

Data will be collected prior to surgery and in the post-operative period by the treating surgeon and at 1,2 and 5 years by blinded subspecialised hand physiotherapists, using standardised data forms (see additional files). These forms will be in locked a filing cabinet.

### Data management

Standardised data forms will be compiled by a researcher blinded to the intervention. Analysis of the data will be performed by a statistician blinded to the treatment. Digitalised data will be stored on a password protected computer.

### Sample size

This study is powered to detect a difference in the rate of complications at the CMCJ. Based on reported complications at the CMCJ in the literature and assuming  $\alpha = 0.05$ ,  $\beta = 0.2$  and allowing for 20% drop out, it is expected that 120 participants will be needed to discriminate between the interventions. We plan to recruit patients for this study over 3–4 years.

### Statistical analysis

All statistical analysis will be performed by a statistician blinded to treatment.

We choose a superiority study design, with the assumption that treatments are equivalent and set out to test this hypothesis. The primary outcome of complications will be analysed by proportional analysis (odds ratio). Continuous secondary outcomes will be analysed by ANOVA. This study is not powered to discriminate between treatments in terms of DASH and PRWE given the MCID (95% confidence interval) is 10 [5–15] and 14 (8–20), respectively [14].

### Discussion

The objective of this trial is to determine whether or not the CMCJ should be fused in TWA. This study will also determine the need for hardware removal and give an insight into how CMCJ is loaded following TWA by assessing the development of problems at this site.

We choose a simple study design with simple outcomes. The primary outcome is complications within 1 year of surgery. TWA are reported to unite at approximately 12 weeks and it is generally accepted that pain and function stabilise by 12 months. We therefore expect that most cases of non-union, hardware failure and soft tissue irritation will be evident by 12 months.

The secondary outcomes that we choose to examine include late complications (up to 5 years), DASH

and PRWE. Nagy reported that union of the CMCJ is hard to determine, especially with hardware in situ [10]. Reigstad reported a significant number of late complications in a cohort of TWA for non-inflammatory wrist arthritis followed up for a mean of 11 years [15]. We therefore felt it important to extend the follow up period to observe undetected CMCJ non-union, indicated hardware breakage and development of CMCJ pain due to extended periods of abnormal load on the joint, as well as other complications which may be undetected within 12 months of TWA.

This randomised clinical trial will provide insight into the outcomes of TWA and may facilitate recommendation of a superior surgical method. We plan to begin recruitment of participants in early 2021.

### Abbreviations

ANOVA: Analysis of variance; CMCJ: Carpometacarpal joint; CT: Computer tomography; DASH: Disabilities of the arm shoulder and hand; IBRA: International Bone Research Association; MCID: Minimal important difference; PRWE: Patient-rated wrist evaluation; SPIRIT: Standard Protocol Items: Recommendations for Interventional Trials; TWA: Total wrist arthrodesis

### Supplementary Information

The online version contains supplementary material available at <https://doi.org/10.1186/s12891-021-04644-4>.

**Additional file 1.** Initial patient data form.

**Additional file 2.** Patient review data form.

**Additional file 3.** Surgeon review data form.

### Acknowledgements

Not applicable.

### Authors' contributions

DO conceived, designed and authored the protocol. DP is the research coordinator, drafted the protocol and primary contact for the study. CR, IP and MD will enrol and perform surgery. PS helped with trial design and is head of the Trauma and the Orthopaedics Research Unit. All authors have read and agree with the contents of manuscript. The author(s) read and approved the final manuscript.

### Funding

This trial is supported by the International Bone Research Association (IBRA), Basel, Switzerland. The funding body played no role in the design of the study and will not be involved in collection, analysis, and interpretation of data and writing the manuscript.

### Availability of data and materials

Not applicable.

### Declarations

#### Ethics approval and consent to participate

This study is approved by the Canberra Hospital Human Ethics Committee (ACT Health Reference: 2020.ETH.00207, REGIS Reference: 2020/ETH02083). Participants will be provided with verbal and written information and must sign a consent form in order to participate in this trial.

#### Consent for publication

Not applicable.

**Competing interests**

The authors declare that they have no competing interests.

Received: 3 May 2021 Accepted: 24 August 2021

Published online: 08 September 2021

**References**

- Jebson PJ, Adams BD. Wrist arthrodesis: review of current techniques. *J Am Acad Orthop Surg* [Internet]. 2001;9(1):53–60. Available from: <http://ovidsp.ovid.com/ovidweb.cgi?T=JS&PAGE=reference&D=emed7&NEWS=N&AN=33441160>. <https://doi.org/10.5435/00124635-200101000-00006>.
- Dupont M, Vainio K. Arthrodesis of the wrist in rheumatoid arthritis. A study of 140 cases. *Ann Chir Gynaecol Fenn* [Internet]. 1968;57(4):513–9 Available from: <http://ovidsp.ovid.com/ovidweb.cgi?T=JS&PAGE=reference&D=med1&NEWS=N&AN=5731324>.
- Owen DH, Agius PA, Nair A, Perriman DM, Smith PN, Roberts CJ. Factors predictive of patient outcome following total wrist arthrodesis. *Bone Jt J* [Internet]. 2016 May;98(5):647–53. Available from: <http://europepmc.org/a/bstract/med/27143736>. <https://doi.org/10.1302/0301-620X.98B5.35638>.
- Hernekamp JF, Schönle P, Kremer T, Kneser U, Bickert B. Low-profile locking-plate vs. the conventional AO system: early comparative results in wrist arthrodesis. *Arch Orthop Trauma Surg* [Internet]. 2020;140(3):433–9. Available from: <http://actheathlibrary.idm.oclc.org/login?url=http://search.ebscohost.com/login.aspx?direct=true&db=ccm&AN=141860246&site=ehost-live>
- Koch O, Alexander AN, Olorunju S, McLoughlin HA, Le Roux TL. Grip strength following total wrist arthrodesis using the same hand as reference: a prospective study. *South African Orthop J*. 2019:41–5.
- Houshian S, Schröder HA. Wrist arthrodesis with the AO titanium wrist fusion plate: A consecutive series of 42 cases. *J Hand Surg Br* [Internet]. 2001 Aug 1 [cited 2020 Apr 17];26 B(4):355–9. Available from: <http://www.ncbi.nlm.nih.gov/pubmed/11469839>.
- Weiss APC, Hastings H. Wrist arthrodesis for traumatic conditions: a study of plate and local bone graft application. *J Hand Surg Am*. 1995;20(1):50–6. [https://doi.org/10.1016/S0363-5023\(05\)80058-9](https://doi.org/10.1016/S0363-5023(05)80058-9).
- Meads S, Meads BM, Scougall PJ, Hargreaves IC. Wrist arthrodesis using a Synthes wrist fusion plate. *J Hand Surg Am*. 2003;41(6):4–7. [https://doi.org/10.1016/S0266-7681\(03\)00146-3](https://doi.org/10.1016/S0266-7681(03)00146-3).
- Ozer K, Hak D. Clinically successful total wrist fusion using cancellous bone allograft. *Curr Orthop Pract* [Internet]. 2010 Nov [cited 2020 Apr 19];21(6):582–5. Available from: <http://actheathlibrary.idm.oclc.org/login?url=http://search.ebscohost.com/login.aspx?direct=true&db=ccm&AN=104967881&site=ehost-live>
- Nagy L, Büchler U. AO-wrist arthrodesis: with and without arthrodesis of the third carpometacarpal joint. *J Hand Surg Am* [Internet]. 2002;27(6):940–7. Available from: <http://ovidsp.ovid.com/ovidweb.cgi?T=JS&PAGE=reference&D=emed7&NEWS=N&AN=35439761>. <https://doi.org/10.1053/jhsu.2002.35885>.
- Berling SE, Kiefhaber TR, Stern PJ. Hardware-related complications following radiocarpal arthrodesis using a dorsal plate. *J Wrist Surg* [Internet]. 2015;4(1):56–60 Available from: <https://pubmed.ncbi.nlm.nih.gov/25709880>.
- Rancy SK, Ek ET, Paul S, Hotchkiss RN, Wolfe SW. Nonspanning Total wrist arthrodesis with a low-profile locking plate. *J Wrist Surg* [Internet]. 2018;7(02):127–32. Available from: <https://doi.org/10.1055/s-00000183>.
- El-Shennawy M, Nakamura K, Patterson RM, Viegas SF. Three-dimensional kinematic analysis of the second through fifth carpometacarpal joints. *J Hand Surg Am* [Internet]. 2001 [cited 2021 Feb 10];26(6):1030–5. Available from: <https://pubmed.ncbi.nlm.nih.gov/11721246/>
- Sorensen A, Howard D, Tan WH, Ketchersid J, Calfee RP, Calfee R. Minimal clinically important differences of three patient-rated outcomes instruments key terms DASH; difference; minimal clinically important; PRWE. *J Hand Surg Am* [Internet]. 2013;38(4):641–9. Available from: <https://www.ncbi.nlm.nih.gov/pmc/articles/PMC3640345/pdf/nihms452783.pdf>. <https://doi.org/10.1016/j.jhsa.2012.12.032>.
- Reigstad O, Holm-Glad T, Korslund J, Grimsgaard C, Thorildsen R, Røkkum M, et al. High re-operation and complication rates 11 years after arthrodesis of the wrist for non-inflammatory arthritis. *Bone Joint J* [Internet]. 2019;101-B(7):852–9. Available from: <http://ovidsp.ovid.com/ovidweb.cgi?T=JS&PAGE=reference&D=med16&NEWS=N&AN=31256671>. <https://doi.org/10.1302/0301-620X.101B7.BJ-2018-0943.R4>.

**Publisher's Note**

Springer Nature remains neutral with regard to jurisdictional claims in published maps and institutional affiliations.

**Ready to submit your research? Choose BMC and benefit from:**

- fast, convenient online submission
- thorough peer review by experienced researchers in your field
- rapid publication on acceptance
- support for research data, including large and complex data types
- gold Open Access which fosters wider collaboration and increased citations
- maximum visibility for your research: over 100M website views per year

**At BMC, research is always in progress.**

Learn more [biomedcentral.com/submissions](https://biomedcentral.com/submissions)

