


RESEARCH ARTICLE

Open Access



The expression of substance P and calcitonin gene-related peptide is associated with the severity of tendon degeneration in lateral epicondylitis

Soo-Hong Han^{1†}, Hyung Kyung Kim^{2†}, Yoon Jang¹, Hyeon Hae Lee¹, Jeongbae Rhie³, Donghun Han¹, Jongbeom Oh¹ and Soonchul Lee^{1*} 

Abstract

Background: In this study, we investigated whether substance P (SP) or calcitonin gene-related peptide (CGRP) expression is associated with tendon degeneration in patients with lateral epicondylitis.

Methods: Twenty-nine patients who underwent surgical treatment for lateral epicondylitis were enrolled in the final analyses. Extensor carpi radialis brevis tendon origins were harvested for histological analysis.

Results: SP and CGRP immunostaining were negative in healthy tendons but positive in degenerative tendons; moreover, their immunoreactivity increased with degeneration severity. Univariate analysis indicated that variables such as the preoperative visual analog scale (VAS) score or SP or CGRP expression levels were significantly associated with the Movin score. However, multivariate analysis revealed that only higher SP and/or CGRP signals were associated with higher Movin scores. Elevations in SP or CGRP expression were also linked with significantly severe preoperative VAS scores.

Conclusion: We demonstrated that tendon degeneration severity is associated with increased SP and CGRP expression in the biopsy samples of lateral epicondylitis.

Keywords: Substance P, Calcitonin gene-related peptide, Tendon degeneration, Lateral epicondylitis, Tendinopathy

Background

Lateral epicondylitis, commonly known as tennis elbow, refers to a pathological condition with varying degrees of pain or point tenderness at the common extensor origin [1–3]. This condition has an annual estimated prevalence of 1–3% in the general population and is one of the most frequently diagnosed elbow conditions typically

occurring after strenuous musculoskeletal movements or microtrauma incidents [4]. Since its first description in 1883, many authors have proposed various explanations such as micro-tears owing to repetitive loading, degenerative changes owing to abnormal vascularity, and oxygen free-radical injuries [5–8]. Nonetheless, the multifactorial nature of lateral epicondylitis hinders the understanding of its exact biochemical mechanism [9].

Histopathologically, lateral epicondylitis is characterized by angiofibroblastic proliferation with collagen tissue fibrillation and chronic inflammation. The presence of a disorganized extracellular matrix with increased angiogenesis, immature fibroblasts, and

* Correspondence: Lsceline78@gmail.com

[†]Soo-Hong Han and Hyung Kyung Kim contributed equally to this work, should be considered as co-first authors.

¹Department of Orthopaedic Surgery, CHA Bundang Medical Center, CHA University School of Medicine, 335 Pangyo-ro, Bundang-gu, Gyeonggi-do, Seongnam-si 13488, Republic of Korea

Full list of author information is available at the end of the article



© The Author(s). 2021 **Open Access** This article is licensed under a Creative Commons Attribution 4.0 International License, which permits use, sharing, adaptation, distribution and reproduction in any medium or format, as long as you give appropriate credit to the original author(s) and the source, provide a link to the Creative Commons licence, and indicate if changes were made. The images or other third party material in this article are included in the article's Creative Commons licence, unless indicated otherwise in a credit line to the material. If material is not included in the article's Creative Commons licence and your intended use is not permitted by statutory regulation or exceeds the permitted use, you will need to obtain permission directly from the copyright holder. To view a copy of this licence, visit <http://creativecommons.org/licenses/by/4.0/>. The Creative Commons Public Domain Dedication waiver (<http://creativecommons.org/publicdomain/zero/1.0/>) applies to the data made available in this article, unless otherwise stated in a credit line to the data.

inflammatory cells can be observed in the disrupted tendon [10–16]. Nociceptive neuromediators act as primary components in pain pathophysiology. Multiple studies have specifically implicated the neuropeptides, Substance P (SP) and calcitonin gene-related peptide (CGRP), as potential tendinopathy-related factors [5, 17–20].

The expression of SP, CGRP, and their receptor, neurokinin-1, has been reported at the proximal extensor carpi radialis brevis (ECRB) tendon, the main pathological lesion in lateral epicondylitis [17, 21]. Peterson et al. used positron emission tomography and the neurokinin-1 specific radioligand to examine patients with lateral epicondylitis and found that the radioligand signal intensity was higher in the affected arm than in the unaffected arm [22]. Additionally, Fedorczyk et al. showed increased endogenous SP expression before tenocyte hypercellularity upon tendon loading [23]. The findings collectively indicate the importance of SP or CGRP in the pathogenesis of lateral epicondylitis [17–20].

However, to the best of our knowledge, no study has reported the relationship between SP or CGRP expression and the tendon degeneration level in lateral epicondylitis. Thus, we investigated the associations of SP and CGRP protein expression with the histological severity of tendon degeneration. We hypothesized that SP and CGRP expression would be associated with tendon degeneration severity in patients with lateral epicondylitis.

Methods

Design

This research was approved by CHA Bundang Medical Center, CHA University, Institutional Review Board (Registration no. 2013–01–174-012). All experiments were performed in accordance with the Declaration of Helsinki, and the protocol was approved by the institutional review board. Informed consent was obtained from all the participants. Clinical and histological data of the study participants from January 2010 to December 2015 were collected and analyzed.

Study population

Only patients with a clinical diagnosis of lateral epicondylitis were included in this study. All patients had well-localized radioulnar joint pain and tenderness over the lateral epicondyle. Pain was also evoked by provocation tests, which included the following physical examinations: gripping resisted wrist extension with radial deviation or resisted third digit extension. Surgical treatment was performed on patients who had failed non-operative treatment for a minimum of 9 months, including the use of braces, physiotherapy (ultrasound, electrical stimulation, heat therapy, and manipulation), and non-steroidal anti-inflammatory medication, single/multiple platelet-

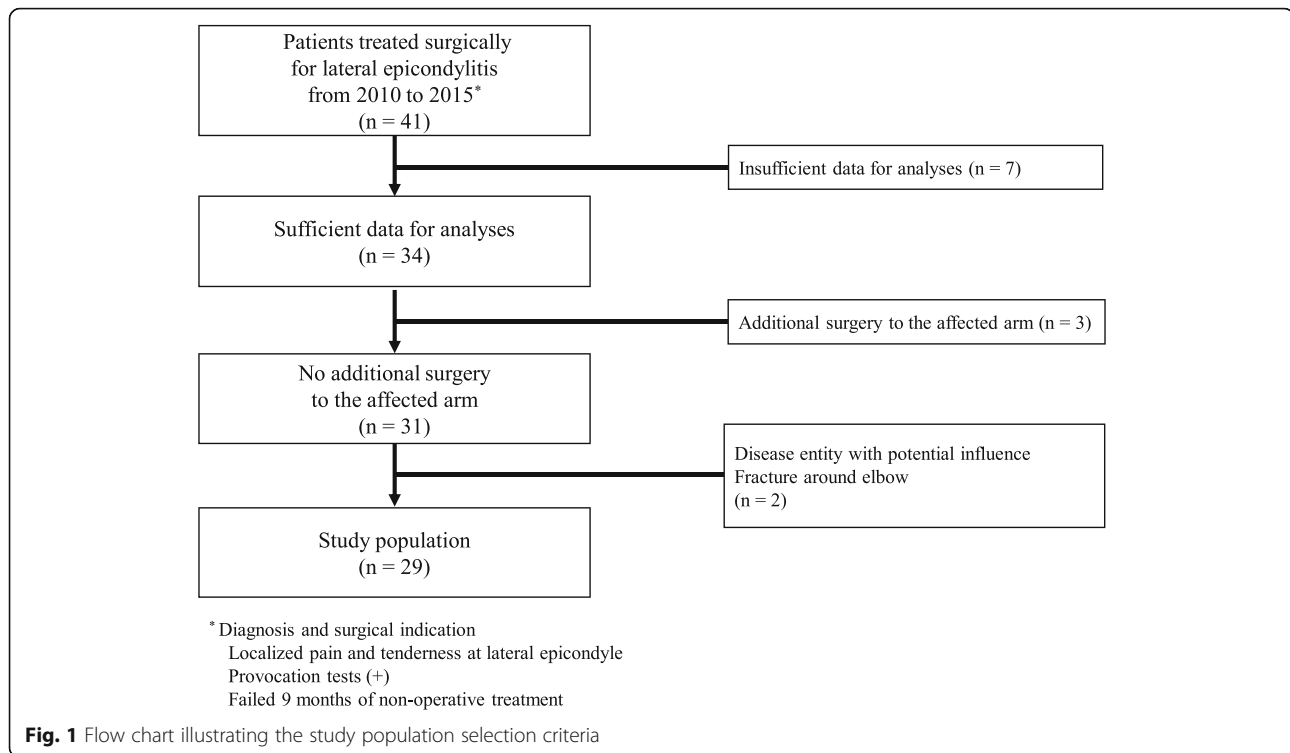
rich plasma, or corticosteroid injection. We judged the failure of non-operative treatment at least 3 months after the last injection. A modified Nirschl procedure was performed on all patients by a single surgeon [24] and the patients were followed up for at least 2 years after surgery. Forty-one patients were originally identified; data from seven of these patients were insufficient for analysis and were excluded. Three patients with a history of previous surgery in the affected arm were excluded, along with two others who had pre-existing arm conditions such as rheumatoid arthritis or medial epicondylitis. Twenty-nine elbows (25 dominant arms and four non-dominant arms) in 29 patients (14 males and 15 females) were enrolled in the study (Fig. 1). The mean patient age was 48 years (range, 38–58 years). Eight patients were included in the control group (five males and three females). The mean age of the control group was 35 years (range, 22 to 47 years). Remains of hamstring (seven patients) or patellar tendon (one patient) from other patients undergoing anterior cruciate ligament reconstruction were used as healthy controls to histologically compare and validate the harvested specimens from patients with lateral epicondylitis [25].

Preoperative and postoperative clinical data

The following clinical data were collected at the outpatient department for all patients: gender, age, job, a record of industrial accident compensation, dominant or non-dominant arm, smoking history, alcohol consumption, plain radiograph of the elbow during operation, body mass index, and preoperative symptom duration. In addition to the baseline patient data, postoperative symptom improvements, range of motion, and radiographic changes were also evaluated. Patients were obliged to complete two self-assessing questionnaires for pain severity and functional disability. The visual analog scale (VAS), one of the most sensitive pain rating scales, was utilized to determine pain on a scale from 0 to 10 [16]. The mean disability of the arm, shoulder, and hand (DASH) outcomes measured the functional defects at the upper extremity on a scale of 100, with a higher score indicating a greater level of disability [26, 27]. Both VAS and DASH scores were obtained before and 2 years after surgery. The measurements taken after 2 years were assumed to reflect the final clinical outcomes. The patient demographics and clinicopathological data are summarized in Table 1.

Pathological review: evaluation of tendon degeneration

Biopsy specimens (approximately 1 cm³) were taken from ECRB tendon origins during surgery; they appeared dull, gray, friable, and edematous. Sampling was performed only after informed consent was obtained. Tendon degeneration in each harvested tissue was analyzed



quantitatively. All specimens were fixed in 10% formalin, embedded in paraffin, and cut into 4- μ m serial sections for H&E and Alcian blue staining. H&E staining was performed using an automated staining machine (Leica ST5010 Autostainer XL). Alcian blue (pH 2.5) staining was performed on deparaffinized sections according to the standard protocols: Alcian blue staining at room temperature for 30 min followed by nuclear fast red staining for 3 min. The Movin score was adopted to classify degrees of tendinopathy based on H&E and Alcian blue staining [28]. The 4-point scoring system comprised 0 (normal), 1 (mild), 2 (moderate), and 3 (severe), by including the following assessment criteria: fiber structure, fiber arrangement, size and shape of cell nuclei, collagen stainability, extracellular matrix, vessel density, hyalinization of stroma, and proteoglycan content (Supplemental Table 1) [29]. All samples were blindly examined by an orthopedic surgeon, pathologist, and a medical student after proper training.

Pathological review: Immunohistochemical staining for SP and CGRP

Immunohistochemical staining for SP and CGRP was performed on lateral epicondylitis tendon specimens. All steps were performed following the manufacturer's instructions, with minor modifications. Samples were sliced into 4 μ m thick tissue sections from formalin-

fixed, paraffin-embedded tissue blocks for immunohistochemical staining using the Bond Polymer Intense Detection system (Vision BioSystems, Victoria, Australia). After deparaffinization using Bond Dewax Solution (Vision BioSystems), antigen retrieval was performed for 30 min at 100 °C using Bond ER Solution (Vision BioSystems). Endogenous peroxidase activity was quenched for 5 min at room temperature. Then, the sections were incubated for 15 min at ambient temperature with mouse monoclonal antibodies against SP (1: 400, Abcam, Cambridge, UK) or CGRP (1: 200, Abcam, Cambridge, UK). A biotin-free polymeric horseradish peroxidase-linker antibody conjugate system was utilized to visualize the spatial and temporal localization of SP and CGRP. The sections were counterstained with hematoxylin for observation under a light microscope (Eclipse Ni-U, Nikon, Japan).

Pathological review: quantitative evaluation of SP and CGRP protein expression

Digital images of SP and CGRP immunostained sections were randomly obtained from five areas of the degenerative region under 400x magnification. Each image was analyzed using the digital image analysis program, ImageJ (National Institute of Health, Bethesda, Maryland, USA). Quantitative analysis was performed by counting positive brown particles in immunohistochemistry pixel-by-pixel. The Color Deconvolution plugin and H-DAB

Table 1 Patient Demographics and Clinicopathological Data

Variables	No. (%) or Mean \pm SD
Gender	
Male	14 (48.28)
Female	15 (51.72)
Age (years)	48.41 \pm 10
Job ^a	
Housekeeping	4 (13.79)
White-collar	12 (41.38)
Blue-collar	13 (44.83)
Industrial accident compensation ^a	
No	27 (96.4)
Yes	2 (7.1)
Affected arm ^a	
Dominant	25 (86.21)
Non-dominant	4 (13.79)
Smoking ^a	
No	22 (85.86)
Yes	7 (24.13)
Alcohol consumption ^a	
None	20 (68.96)
Social	7 (24.13)
Heavy ^c	2 (6.9)
Plain radiograph at operation ^a	
Normal	13 (44.83)
Abnormal ^d	16 (55.17)
Body mass index (kg/m ²)	23.74 \pm 3.08
Preoperative	
Symptom duration (months)	22.31 \pm 15.91
VAS score	4.62 \pm 1.21
DASH score	58.31 \pm 13.63
Postoperative ^a	
VAS score	0.9 \pm 1.3
DASH score	15.1 \pm 12.7
Postoperative range of motion ^{a, b}	
Full	27 (96.4)
Limited	2 (7.1)
Neuropeptide expression	
SP	2.05 \pm 1.29
CGRP	5.11 \pm 5.03

SD Standard deviation, SP Substance P, CGRP Calcitonin gene-related peptide, ^acategorical variables, ^bevaluated at two-year follow-up (two years after operation). ^cindicates the patient who drinks on five or more days per month. ^dincludes sclerotic change of the lateral condyle and calcification of the extensor tendon origin

vector enabled isolation of the brown image composed of positive particles from the original picture. The brown image was converted into a black-and-white photo so

that the ImageJ program could detect the positive particles on a black-and-white scale. The focus of the field in each image may be uneven; thus, three montages were generated and the measurement threshold was determined to obtain more accurate values (Fig. 2) [30, 31]. The area fraction value was measured in ImageJ by dividing the pixels of the immunopositive area with the pixels of the total area. This value was used as the staining score. Additionally, for the normalization of protein expression, the number of tenocytes was measured semi-manually using ImageJ. The cell count jar plugin in ImageJ enables direct marking of a cell image. Every tenocyte in each image was marked manually, and the program measured the Loser total cell number in each marked image.

Statistical analysis

We determined the overall summary statistics for continuous and categorical variables in terms of means and standard deviations, and frequencies and percentages, respectively. Intra-observer and inter-observer reliability of histologic evaluation were determined using intraclass correlation coefficients based on the 95% confidence interval for absolute agreement. A correlation coefficient of 0–0.2 indicated poor reliability; 0.21–0.4 was fair, 0.41–0.6 was moderate, 0.61–0.8 was good, and greater than 0.81 indicated excellent reliability. After the correlation analyses of independent variables using Pearson's correlation test, univariate analyses were performed to evaluate associations between variables and tendon degeneration (shown as Movin score). Linear regression models were applied for continuous variables, whereas analyses of variance and t-tests were used for categorical variables. After univariate analyses, various contributing factors including SP, CGRP expression, and several other possible confounders such as sex, age, job, presence of medical compensation, past medical history, invasion of the dominant/non-dominant arm, preoperative symptom duration, preoperative plain radiograph of the elbow, range of motion of the arm, body mass index, smoking history, and alcohol consumption were entered into a stepwise multiple regression model to investigate their individual and combined effects on tendon degeneration. Final variables were selected based on the model suitability scales such as adjusted R square, Akaike information criterion, and Mallows' Cp. Multicollinearity was tested using the variance-inflation factors function in R (R Foundation for Statistical Computing, Vienna, Austria), and multiple linear models were verified using the Olsrr package. All statistical analyses were performed using the statistical software, R. The statistical significance threshold was set at $p < 0.05$ (Bonferroni correction was performed to account for multiple tests).

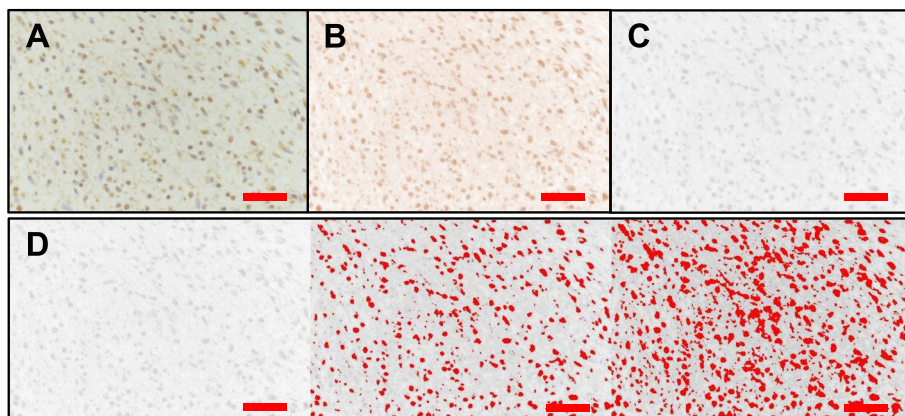


Fig. 2 Quantitative image analyses of SP and CGRP expression. Quantitative analysis was achieved by counting the positive brown particles pixel-by-pixel in immunohistochemistry images using ImageJ (National Institute of Health, Bethesda, Maryland, USA). First, digital images of SP and CGRP immunostaining were obtained (a). Next, the color deconvolution plugin was used to isolate immunopositive particles into the brown image from the original image using the H-DAB vector (b). The positive particles of the brown image were converted into black and white images for recognition (c). Three montages of each image were generated for accurate measurements and threshold determination, and the positive signal area was measured in pixels (d). SP, substance P; CGRP, calcitonin gene-related peptide; magnification, $\times 400$; scale bar = 50 μm

Results

No complications such as stiffness or instability of the elbow, nerve injury, or infection occurred after surgery. Overall, pain and elbow function scores improved in all patients after the operation. Visual analog scale (VAS) scores declined significantly from a preoperative value of 4.62 (range, 3–7) to a two-year follow-up value of 1.06 (range, 0–3) ($p < 0.05$). The DASH score decreased from 57.23 (range, 30–83.3) before surgery to 17.82 (range, 0–42) at the two-year follow-up ($p < 0.05$).

Correlation tests between each parameter indicated that the postoperative VAS score and postoperative DASH score showed strong correlations ($r = 0.85$, $p < 0.001$); therefore, only postoperative DASH scores were used in the following analyses (Supplemental Fig. 1). Additionally,

univariate analysis results revealed that SP and CGRP expression were significantly related to the preoperative VAS score ($r = 0.61$, $p = 0.0006$ for SP expression and $r = 0.39$, $p = 0.034$ for CGRP expression) (Fig. 3). This suggests that patients with higher SP and CGRP expression are more likely to experience severe pain before surgery. However, the correlation test results suggested that postoperative improvement (postoperative DASH score) was not related to SP or CGRP levels ($r = 0.14$, $p = 0.36$ for SP and $r = 0.13$, $p = 0.23$ for CGRP).

Tendons with severe histological degeneration had concomitantly high SP and CGRP protein expression

For the histological analyses, the inter-observer and intra-observer reliabilities were 0.79 (good) and 0.83

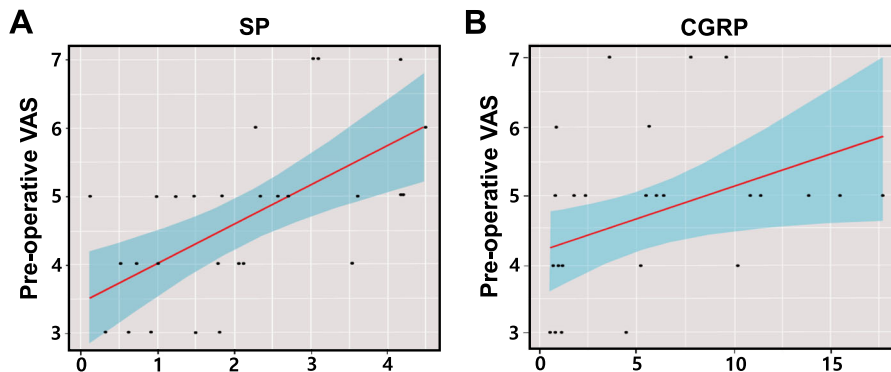


Fig. 3 Correlations between SP or CGRP expression and preoperative VAS scores. There were significant positive correlations between SP (a) and CGRP (b) expression and preoperative VAS scores (SP: $p < 0.05$, $r = 0.61$, CGRP: $p < 0.05$, $r = 0.39$). VAS, visual analog scale; SP, substance P; CGRP, calcitonin gene-related peptide. The score on the x-axis shows the staining score, which was calculated by dividing the pixels of the immunopositive area with the pixels of the total area

(excellent), respectively. Tendons harvested from patients with lateral epicondylitis were validated by comparison with a healthy control group. All tendons from lateral epicondylitis showed characteristic tendon degeneration features at varying degrees. Samples presented disorganized tendon fibers with higher cellularity and vessel formation in hematoxylin and eosin (H&E) staining. In Alcian blue staining, the degenerative tendons showed marked amounts of ground substances consisting of proteoglycans and glycosaminoglycan with several mucoid patches and vacuoles between fibers. They also showed exceedingly increased SP and CGRP immunoreactive area fractions compared to the healthy control group.

Next, the staining scores for SP and CGRP were determined quantitatively using immunohistochemistry images. The pixels with positive brown particles were counted using ImageJ (Fig. 2). Mean staining scores in specimens were found to be 2.05 for SP and 5.11 for CGRP. In contrast, healthy controls were negative for SP

and CGRP immunohistochemical staining of tenocytes (Fig. 4). Next, the total expression of SP and CGRP was normalized to the cell number because the degenerated tendons had more cells. The results demonstrated that tendon samples with a higher Movin score had significantly higher SP and CGRP expression per cell (Supplemental Fig. 2).

Higher SP and/or CGRP expression was associated with greater tendon degeneration (Movin score)

Univariate analyses demonstrated that preoperative VAS score ($r = 0.22$, $p < 0.05$), as well as SP ($r = 0.43$, $p < 0.001$) and CGRP ($r = 0.50$, $p < 0.001$) expression levels were significantly associated with higher Movin scores (Fig. 5). Multiple regression models were generated to determine the parameters influencing the Movin score. SP and CGRP expression scores were selected as associated parameters in stepwise regression, indicating that SP and CGRP expression were highly associated with the extent of tendon degeneration. The results indicated

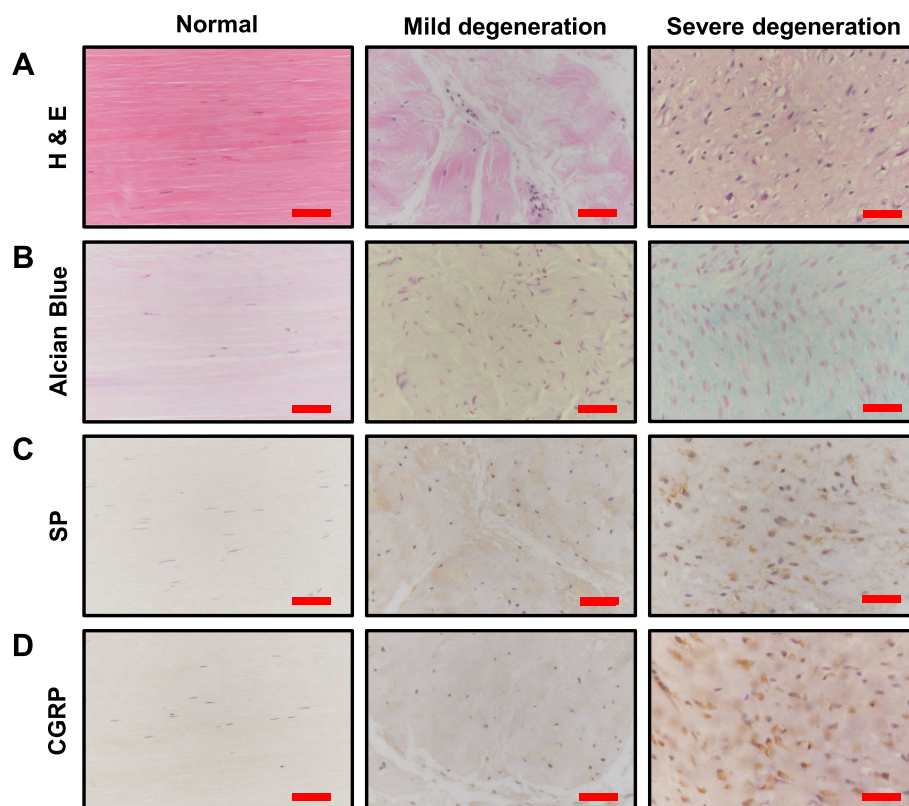


Fig. 4 Representative histologic images of healthy control and degenerated tendons. H&E staining (a) of healthy tendons displayed arrays of straight, compact fibers with linear shaped interfascicular inconspicuous nuclei. As degeneration progressed, the fibers started to lose polarity and became thinner and wavy. Tenocytes increased in number and size, and their nuclei changed into ovoid shape. Alcian blue staining (b) of degenerated tendon tissues showed interfascicular ground substances and acid mucopolysaccharides, which are rarely observed in healthy tendons. SP (c) and CGRP (d) immunoreactions were elevated in proportion with the degree of degenerative changes, but healthy tendons showed negative reactions to immunohistochemical staining. Values below the mean Movin score of 17.5 were defined as mild degeneration. Values above the mean Movin score were defined as severe degeneration. SP, substance P; CGRP, calcitonin gene-related peptide; magnification $\times 400$; scale bar = 50 μm

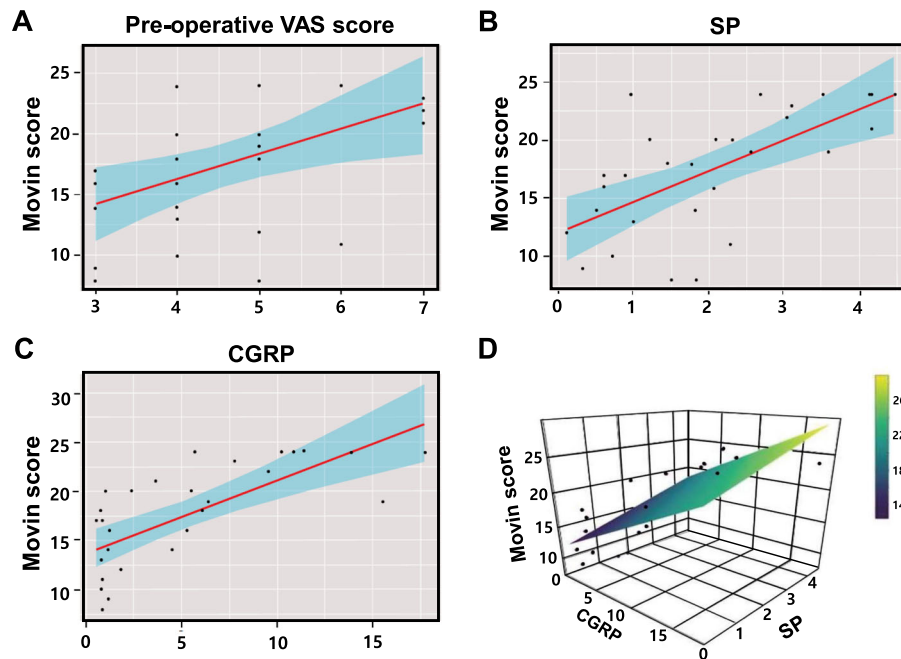


Fig. 5 Correlation of SP and/or CGRP expression with tendon degeneration (Movin score). The association between various variables and tendon degeneration severity (Movin score) was analyzed using the linear regression test. The Movin score was significantly associated with the parameters including preoperative VAS score (a), SP (b), and CGRP (c) expression levels ($r = 0.22, p < 0.05$; $r = 0.43, p < 0.001$; and $r = 0.50, p < 0.001$ respectively). The association of both SP and CGRP with the Movin score was visualized by a three-dimensional graph (d). VAS, visual analog scale; SP, substance P; CGRP, calcitonin gene-related peptide

that the prediction model including SP and CGRP accounted for 52.63% of the Movin score. Preoperative VAS scores were excluded from the analysis because they did not statistically contribute to the model in the adjusted R square, Akaike information criterion, and Mallows Cp (Supplemental Fig. 3). Collectively, the equation was: Prob (Tendon degeneration, Movin score) = $1.38 \times \text{SP expression} + 0.61 \times \text{CGRP expression} + 11.90$. Table 2 summarizes the results of the multiple regression models.

Discussion

Disruption of neuronal regulation, regulated by the neuromediators SP and CGRP, is likely to contribute to tendon degeneration [32]. We hypothesized that either SP or CGRP protein levels would be closely linked to tendon degeneration. Histopathologically quantified data

supported this hypothesis by revealing significant associations between the degrees of tendinopathy and the SP and CGRP levels.

Infection or injury is known to trigger neuropeptide release, which can induce an inflammatory reaction [33]. However, the effect of neuropeptides like SP or CGRP on tendinopathy development or acceleration is debatable. Ljung et al. compared SP and CGRP immunoreactivity between patients with lateral epicondylitis and healthy volunteers, and concluded that neurogenic inflammation may be implicated in the etiology of lateral epicondylitis [21]. Likewise, Uchio et al. demonstrated how neuropeptides (SP and CGRP) and cytokines (interleukin-1 α and tumor growth factor- β) contribute to lateral epicondylitis progression [6]. However, these studies were only conducted on small sampling scales of six and nine patients, respectively.

Table 2 Full Model from Stepwise Multiple Linear Regression Analyses

Dependent variable	Independent variables	Coefficient	95% CI	Adjusted r ²	p-value
Movin score	Intercept	11.90	10.7–13.1	0.60	< 0.05
	SP	1.38	0.73–2.04		
	CGRP	0.61	0.43–0.80		

CI Confidence interval, SP Substance P, CGRP Calcitonin gene-related peptide

Similarly, SP and CGRP levels are reported to be increased in tendon fibroblasts in animal models of collagenase-induced tendinopathy [34]. In this context, SP and CGRP have been highlighted as critical factors in chronic tendon pain and thickening. Gene expression analyses performed by Backman et al. illustrated how mechanical loading on tendon cell cultures significantly increased SP and neurokinin-1 receptor mRNA levels. They also observed increased endogenous SP production in an animal model [35, 36]. Later, the same group recapitulated these changes, including hypercellularity and angiogenesis, by injecting SP close to the tendons in vivo [37]. Zhou et al. also discussed the effects of SP on pluripotent tendon cell proliferation and differentiation in vivo and in vitro in rat patellar tendon injection models [38]. They showed that SP upregulated the expression of non-tenocyte genes but downregulated the expression of tenocyte-related genes during pluripotent stem cell differentiation. Histological examination revealed that SP induced in vivo tissue disorganization, which later developed into tendinopathy.

On the contrary, other studies have reported favorable roles of SP and CGRP in tendon healing processes. Carlsson et al. argued that SP enhances tissue recovery via multiple modalities such as inflammatory response, pain transmission, cellular proliferation, and increased vascular permeability in acute tendon injury or rupture [39]. Fong et al. discovered that cyclic tensile loading of tenocyte cultures along with the administration of exogenous SP, triggers collagen remodeling through its synergistic enhancement of matrix metalloproteinase 3 [32]. Another in vivo study by Steyaert et al. highlighted improvements in tendon recovery rates by injecting SP into the paratendinous region of an acute Achilles tendon injury [40].

In another aspect, Zhou et al. studied the effects of different SP concentrations on in vitro and in vivo tendon-derived stem cells [41]. Low dose SP (0.5 nmol) enhanced tenogenesis by inducing tenocyte-related genes, whereas high-dose SP (5.0 nmol) promoted tendinopathy-like changes in the tendon around the patella by activating non-tenocyte-related genes such as peroxisome proliferator activator receptor γ and collagen type II. Collectively, we can speculate that SP and CGRP have different effects on tendons according to their dosage and duration of exposure.

In this study, we discovered that preoperative VAS scores were significantly related to the SP and CGRP levels. We enlarged the sampling pool by collecting 29 tissue samples for 6 years, with at least a two-year follow-up. These results are consistent with those of previous studies; SP and CGRP are well-known causes of pain, hyperalgesia, vasodilation, and plasma extravasation [42, 43]. Interestingly, postoperative DASH and

VAS scores improved in most cases regardless of SP and CGRP levels in the harvested tissue. Therefore, further research related to this result is warranted.

There are several limitations in our study. Although we demonstrated that SP and CGRP expression was significantly related to the degree of tendinopathy, it is unknown whether there is a causal relationship between neuropeptides and tendinopathy. Second, we managed to diagnose lateral epicondylitis in only clinical instances without the use of imaging studies such as magnetic resonance imaging (MRI). MRI in addition to pathological evaluation could have been helpful in diagnosing and grading the degrees of lateral epicondylitis. Third, statistical bias may have occurred because the expression patterns of healthy control and degenerated tendons were not compared under the same conditions. Hamstring or patella tendons were harvested as controls, which are likely to have been exposed to different physical loading conditions in daily activity. In addition, the healthy controls were much younger on average compared to the patients with lateral epicondylitis. Further, only the relative expression levels of SP and CGRP were compared because there are no known standard levels of SP and CGRP expression in healthy and degenerated tendons.

Conclusions

Our data highlight that both SP and CGRP expression were increased in the tendon samples of lateral epicondylitis and that their expression levels are coupled with the degree of tendon degeneration. Additionally, these nociceptive neuromediators are associated with preoperative pain in lateral epicondylitis, suggesting that SP and CGRP might be related to the development of tendinopathy. Further studies are, therefore, necessary to develop novel therapeutics targeting SP and CGRP for treating tendon degeneration.

Supplementary Information

The online version contains supplementary material available at <https://doi.org/10.1186/s12891-021-04067-1>.

Additional file 1: Supplemental Figure 1. Results of correlation tests between two variables: Correlations matrix. A: Age (years), B: Preoperative symptom duration, C: Preoperative VAS score, D: Preoperative DASH score, E: Postoperative DASH score, F: Postoperative VAS score, G: Body mass index, H: Movin score, I: SP expression, J: CGRP expression, Red box: Significantly correlated values. Values in each square box imply a correlation coefficient (r). VAS, visual analog scale; DASH, disability of arm, shoulder, and hand; SP, substance P; CGRP, calcitonin gene-related peptide.

Additional file 2: Supplemental Figure 2. Normalized SP and CGRP expression per cell. To calculate the SP and CGRP expression per cell, the cell numbers in five representative images were counted and the total SP and CGRP expression was normalized by cell number. The tendon sample with the higher Movin score ($22 \leq \text{score} \leq 24$) was determined to have significantly higher SP and CGRP expression per cell. Data are

expressed as mean \pm standard deviation. * indicates a *p* value less than 0.05. SP, substance P; CGRP, calcitonin gene-related peptide.

Additional file 3: Supplemental Figure 3. Regression model accuracy. Regression model accuracy was tested using the adjusted R square (A), Akaike information criterion (B), and Mallows Cp (C). Models excluding the preoperative VAS score showed better fit in all tests. VAS: visual analog scale.

Additional file 4: Supplemental Table 1. Movin score.

Abbreviations

SP: Substance P; CGRP: Calcitonin gene-related peptide; VAS: Expression, visual analog scale; DASH: Disability of the Arm, Shoulder, and Hand; MRI: Magnetic resonance imaging

Acknowledgments

We thank Erica Sung, Student of Department of Biochemistry, University of Colorado Boulder, College of Arts and Sciences, for manuscript editing.

Authors' contributions

S. H.: Manuscript review and editing. H. K.: Conceptualization; investigation; manuscript review and editing. Y. J.: Manuscript review and editing. H. L.: Data curation. J. R.: Data curation. D. H.: Methodology. J. O.: Methodology. S. L.: Project administration; funding acquisition; formal analysis; writing the original draft. All authors have read and approved the manuscript.

Funding

Role of the funders (NRF and MSIT): Financial support and administrative support.

This work was supported by the Korea Health Technology R&D Project through the Korea Health Industry Development Institute, funded by the Ministry of Health & Welfare, South Korea (grant number HI16C1559) and by the National Research Foundation of Korea (NRF) grant funded by the Korean government (MSIT) (No. 2019R1F1A1060978, 2019R1C1C1004017).

Availability of data and materials

The datasets used and/or analyzed during the current study are available from the corresponding author upon reasonable request.

Ethics approval and consent to participate

This research was approved by CHA Bundang Medical Center, CHA University, Institutional Review Board (registration no. 2013-01-174-012).

Consent for publication

Written informed consent was obtained from all study participants for publication.

Competing interests

The authors declare that they have no competing interests.

Author details

¹Department of Orthopaedic Surgery, CHA Bundang Medical Center, CHA University School of Medicine, 335 Pangyo-ro, Bundang-gu, Gyeonggi-do, Seongnam-si 13488, Republic of Korea. ²Department of Pathology, Kyung Hee University Hospital at Gangdong, Kyung Hee University, College of Medicine, Seoul, Republic of Korea. ³Department of Occupational and Environmental Medicine, Dankook University College of Medicine, Cheonan, Republic of Korea.

Received: 20 August 2020 Accepted: 10 February 2021

Published online: 21 February 2021

References

- Fedorczyk JM. Tennis elbow: blending basic science with clinical practice. *J Hand Ther Off J Am Soc Hand Therapists*. 2006;19(2):146–53.
- Seo JB, Yoon SH, Lee JY, Kim JK, Yoo JS. What is the most effective eccentric stretching position in lateral elbow tendinopathy? *Clin Orthop Surg*. 2018;10(1):47–54.
- Verhaar JA. Tennis elbow. Anatomical, epidemiological and therapeutic aspects. *Int Orthop*. 1994;18(5):263–7.
- Placzek R, Drescher W, Deuretzbacher G, Hempfing A, Meiss AL. Treatment of chronic radial epicondylitis with botulinum toxin a. a double-blind, placebo-controlled, randomized multicenter study. *J Bone Joint Surg Am Volume*. 2007;89(2):255–60.
- Zeisig E, Ljung BO, Alfredson H, Danielson P. Immunohistochemical evidence of local production of catecholamines in cells of the muscle origins at the lateral and medial humeral epicondyles: of importance for the development of tennis and golfer's elbow? *Br J Sports Med*. 2009;43(4):269–75.
- Uchio Y, Ochi M, Ryoke K, Sakai Y, Ito Y, Kuwata S. Expression of neuropeptides and cytokines at the extensor carpi radialis brevis muscle origin. *J Shoulder Elb Surg*. 2002;11(6):570–5.
- Lieber RL, Loren GJ, Fridén J. In vivo measurement of human wrist extensor muscle sarcomere length changes. *J Neurophysiol*. 1994;71(3):874–81.
- Regan W, Wold LE, Coonrad R, Morrey BF. Microscopic histopathology of chronic refractory lateral epicondylitis. *Am J Sports Med*. 1992;20(6):746–9.
- Kannus P, Józsa L. Histopathological changes preceding spontaneous rupture of a tendon. A controlled study of 891 patients. *J Bone Joint Surg Am*. 1991;73(10):1507–25.
- Nirschl RP, Ashman ES. Elbow tendinopathy: tennis elbow. *Clin Sports Med*. 2003;22(4):813–36.
- Rees JD, Maffulli N, Cook J. Management of tendinopathy. *Am J Sports Med*. 2009;37(9):1855–67.
- Bisset L, Beller E, Jull G, Brooks P, Darnell R, Vicenzino B. Mobilisation with movement and exercise, corticosteroid injection, or wait and see for tennis elbow: Randomised trial. *BMJ (Clin Res Ed)*. 2006;333(7575):939.
- Galliani I, Burattini S, Mariani AR, Riccio M, Cassiani G, Falcieri E. Morpho-functional changes in human tendon tissue. *Eur J Histochem EJH*. 2002; 46(1):3–12.
- Maffulli N, Testa V, Capasso G, Ewen SW, Sullo A, Benazzo F, et al. Similar histopathological picture in males with Achilles and patellar tendinopathy. *Med Sci Sports Exer*. 2004;36(9):1470–5.
- Khan KM, Cook JL, Kannus P, Maffulli N, Bonar SF. Time to abandon the "tendinitis" myth. *BMJ (Clin Res Ed)*. 2002;324(7338):626–7.
- Cho BK, Kim YM, Kim DS, Choi ES, Shon HC, Park KJ, et al. Mini-open muscle resection procedure under local anesthesia for lateral and medial epicondylitis. *Clin Orthop Surg*. 2009;1(3):123–7.
- Ljung BO, Forsgren S, Fridén J. Substance P and calcitonin gene-related peptide expression at the extensor carpi radialis brevis muscle origin: implications for the etiology of tennis elbow. *J Orthop Res Off Publ Orthop Res Soc*. 1999;17(4):554–9.
- Fong G, Backman LJ, Alfredson H, Scott A, Danielson P. The effects of substance P and acetylcholine on human tenocyte proliferation converge mechanistically via TGF- β 1. *PLoS One*. 2017;12(3):e0174101.
- Han SH, Choi W, Song J, Kim J, Lee S, Choi Y, et al. The implication of substance P in the development of tendinopathy: A case control study. *Int J Mol Sci*. 2017;18(6):1241.
- Alfredson H, Ljung BO, Thorsen K, Lorentzon R. In vivo investigation of ECRB tendons with microdialysis technique—no signs of inflammation but high amounts of glutamate in tennis elbow. *Acta Orthop Scand*. 2000;71(5):475–9.
- Ljung BO, Alfredson H, Forsgren S. Neurokinin 1-receptors and sensory neuropeptides in tendon insertions at the medial and lateral epicondyles of the humerus. Studies on tennis elbow and medial epicondylalgia. *J Orthop Res Off Publ Orthop Res Soc*. 2004;22(2):321–7.
- Peterson M, Svärdsudd K, Appel L, Engler H, Aarnio M, Gordh T, et al. PET-scan shows peripherally increased neurokinin 1 receptor availability in chronic tennis elbow: visualizing neurogenic inflammation? *PLoS One*. 2013; 8(10):e75859.
- Fedorczyk JM, Barr AE, Rani S, Gao HG, Amin M, Amin S, et al. Exposure-dependent increases in IL-1 β , substance P, CTGF, and tendinosis in flexor digitorum tendons with upper extremity repetitive strain injury. *J Orthop Res Off Publ Orthop Res Soc*. 2010;28(3):298–307.
- Han SH, An HJ, Song JY, Shin DE, Kwon YD, Shim JS, et al. Effects of corticosteroid on the expressions of neuropeptide and cytokine mRNA and on tenocyte viability in lateral epicondylitis. *J Inflamm (London, England)*. 2012;9(1):40.
- Han SH, Kim HK, Ahn JH, Lee DH, Baek M, Ye G, et al. A protocol to acquire the degenerative tenocyte from humans. *J Vis Exp*. 2018;136):57634.
- Jensen MP, Turner JA, Romano JM, Fisher LD. Comparative reliability and validity of chronic pain intensity measures. *Pain*. 1999;83(2):157–62.

27. Beaton DE, Katz JN, Fossel AH, Wright JG, Tarasuk V, Bombardier C. Measuring the whole or the parts? Validity, reliability, and responsiveness of the disabilities of the arm, shoulder and hand outcome measure in different regions of the upper extremity. *J Hand Ther Off J Am Soc Hand Therapists*. 2001;14(2):128–46.
28. Loppini M, Longo UG, Niccoli G, Khan WS, Maffulli N, Denaro V. Histopathological scores for tissue-engineered, repaired and degenerated tendon: a systematic review of the literature. *Curr Stem Cell Res Ther*. 2015; 10(1):43–55.
29. Maffulli N, Longo UG, Franceschi F, Rabitti C, Denaro V. Movin and Bonar scores assess the same characteristics of tendon histology. *Clin Orthop Relat Res*. 2008;466(7):1605–11.
30. Jensen EC. Quantitative analysis of histological staining and fluorescence using ImageJ. *Anat Rec (Hoboken)*. 2013;296(3):378–81.
31. Papadopoulos F, Spinelli M, Valente S, Foroni L, Orrico C, Alviano F, et al. Common tasks in microscopic and ultrastructural image analysis using ImageJ. *Ultrastruct Pathol*. 2007;31(6):401–7.
32. Fong G, Backman LJ, Hart DA, Danielson P, McCormack B, Scott A. Substance P enhances collagen remodeling and MMP-3 expression by human tenocytes. *J Orthop Res Off Publ Orthop Res Soc*. 2013;31(1):91–8.
33. Russo AF. Overview of neuropeptides: awakening the senses? *Headache*. 2017;57(Suppl:37–46):37–46.
34. Lui PP, Chan LS, Fu SC, Chan KM. Expression of sensory neuropeptides in tendon is associated with failed healing and activity-related tendon pain in collagenase-induced tendon injury. *Am J Sports Med*. 2010;38(4):757–64.
35. Backman LJ, Fong G, Andersson G, Scott A, Danielson P. Substance P is a mechanoresponsive, autocrine regulator of human tenocyte proliferation. *PLoS One*. 2011;6(11):e27209.
36. Backman LJ, Andersson G, Wennstig G, Forsgren S, Danielson P. Endogenous substance P production in the Achilles tendon increases with loading in an in vivo model of tendinopathy-peptidergic elevation preceding tendinosis-like tissue changes. *J Musculoskelet Neuronal Interact*. 2011;11(2):133–40.
37. Andersson G, Backman LJ, Scott A, Lorentzon R, Forsgren S, Danielson P. Substance P accelerates hypercellularity and angiogenesis in tendon tissue and enhances paratendinitis in response to Achilles tendon overuse in a tendinopathy model. *Br J Sports Med*. 2011;45(13):1017–22.
38. Zhou B, Zhou Y, Tang K. The effects of substance P on pluripotent tendon cells: an in vitro and in vivo study. *J Musculoskelet Neuronal Interact*. 2014; 14(3):349–58.
39. Carlsson O, Schizas N, Li J, Ackermann PW. Substance P injections enhance tissue proliferation and regulate sensory nerve ingrowth in rat tendon repair. *Scand J Med Sci Sports*. 2011;21(4):562–9.
40. Steyaert AE, Burssens PJ, Verbruyse CW, Vanderstraeten GG, Verbeek RM. The effects of substance P on the biomechanical properties of ruptured rat Achilles' tendon. *Arch Phys Med Rehabil*. 2006;87(2):254–8.
41. Zhou Y, Zhou B, Tang K. The effects of substance P on tendinopathy are dose-dependent: An in vitro and in vivo model study. *J Nutr Health Aging*. 2015;19(5):555–61.
42. Yan D, Liu X, Guo SW. Neuropeptides substance P and calcitonin gene related peptide accelerate the development and fibrogenesis of endometriosis. *Sci Rep*. 2019;9(1):2698.
43. Greco R, Tassorelli C, Sandrini G, Di Bella P, Buscone S, Nappi G. Role of calcitonin gene-related peptide and substance P in different models of pain. *Cephalalgia*. 2008;28(2):114–26.

Publisher's Note

Springer Nature remains neutral with regard to jurisdictional claims in published maps and institutional affiliations.

Ready to submit your research? Choose BMC and benefit from:

- fast, convenient online submission
- thorough peer review by experienced researchers in your field
- rapid publication on acceptance
- support for research data, including large and complex data types
- gold Open Access which fosters wider collaboration and increased citations
- maximum visibility for your research: over 100M website views per year

At BMC, research is always in progress.

Learn more biomedcentral.com/submissions

